

Laser Resection Technique and Results of Multiple Lung Metastasectomies Using a New 1,318 nm Nd:YAG Laser System

Axel Rolle, MD, PhD,^{1*} Arpad Pereszlenyi,¹ Rainer Koch,² Beata Bis,¹ and Barbara Baier¹

¹Department of Thoracic and Vascular Surgery, Centre of Pneumology and Thoracic Surgery, Coswig/Dresden, Germany

²Department of Informatics, University Carl Gustav Carus, Dresden, Germany

Background and Objectives: Advantages of a new 1,318 nm Nd:YAG laser based on multiple lung metastasectomies are shown.

Study Design/Materials and Methods: Ninety-three percent of 328 patients with metastases (8/patient, range 1–124) had precision laser resections (lobectomy-rate reduced to 7%); this laser delivers 20 kW/cm² 1,318 nm power densities with 400 μm fibers, and a focussing handpiece. Absorption in water is tenfold higher.

Results and Conclusions: Between 1/1996 and 12/2003 in 328 patients (164 males/females, 61 years) 3,267 nodules were removed. Pathologic examination revealed 2,546 metastases (range 3–80 mm) from kidney ($n = 112$), colorectal ($n = 91$), and breast cancers ($n = 35$). In 85% of patients where the complete resection was achieved the 5-year survival was 41%. For remaining 15% (incomplete resection) the 5-year survival was 7%. Five-year survival for patients with 10 (and more) metastases was 28%, for patients with 20 (and more) was 26%. No 30-day mortality was observed.

Conclusion: This new laser system facilitates any kind of parenchymal lung resection in lobe-sparing manner and in case of complete resection improves significantly the survival. *Lasers Surg. Med.* 38:26–32, 2006.

© 2006 Wiley-Liss, Inc.

Key words: 1,318 nm Nd:YAG laser; lung metastasectomy; lung parenchymal sparing resection

INTRODUCTION

Since the first steps in thoracic surgery more than 100 years ago there has been a search for the best technique for parenchymal resection. Even superficial 1 cm deep electrocautery incision of the inflated lung results in bleeding and considerable air leaks (Fig 1a,b). With the use of ultrasonic knives there is no essential improvement because the ultrasonic waves are immediately changed into heat by the resistance of tissue in the same way as the electromagnetic waves of the cautery. Thus, deep penetration into the tissue for strong coagulation which is observed as a function of laser radiation is not achieved. The standard resection technique for lung parenchyma nowadays is the use of stapling devices. Following mechanical principles they try to overcome bleeding and air fistulae by

pressing the lung tissue between two rows of clamps. The limitation for staplers is given by the thickness of the central parts of the lobes and the diameter of the clamps. Furthermore, there is a considerable loss of tissue due to the geometric straight lines and angles of stapler wedge resection in comparison to precision laser resection which follows the geometry of the tumor (Fig 2a,b).

Surgical resection of pulmonary metastases is today considered a standard therapeutic procedure and is routinely performed in many departments of thoracic surgery for curative potential [1–4]. But due to the limits of standard stapler resection metastasectomy is restricted only to carefully selected cases with five or fewer metastases and the lobectomy rate is between 20% and 30% [2,4]. With this retrospective study we want to demonstrate that this new 1,318 nm Nd:YAG laser system improves any kind of lung metastasectomy and facilitates the lobe sparing resection of a significantly higher number of metastases. Furthermore, the eligibility of patients for metastasectomy can be expanded.

MATERIALS AND METHODS

Lung tissue with 80% water content, very low tissue density, and high shrinking capacity due to variable alveolar air content demonstrates qualities very feasible for photothermal laser resection. One of the most important qualities of laser is the emission of monochromatic light. This means that you can calculate and use the special qualities of one distinct wavelength for tissue effects on a target organ. The challenge to get benefit for all kinds of lung parenchymal resection was to find the best wavelength. In 1985, at a time when bronchoscopical endoluminal laser coagulation and vaporization of central obstructive bronchial carcinoma was routinely performed, LoCicero suggested the application of CO₂ laser on lung

*Correspondence to: Axel Rolle, MD, PhD, Department of Thoracic and Vascular Surgery, Coswig Specialised Hospital, Centre of Pneumology and Thoracic Surgery, Affiliated to the Carl Gustav Carus University Dresden, Neucoswiger Straße 21, D-01640 Coswig/Dresden, Germany.

E-mail: dr.rolle@fachkrankenhaus-coswig.de

Accepted 21 September 2005

Published online 23 January 2006 in Wiley InterScience (www.interscience.wiley.com).

DOI 10.1002/lsm.20259

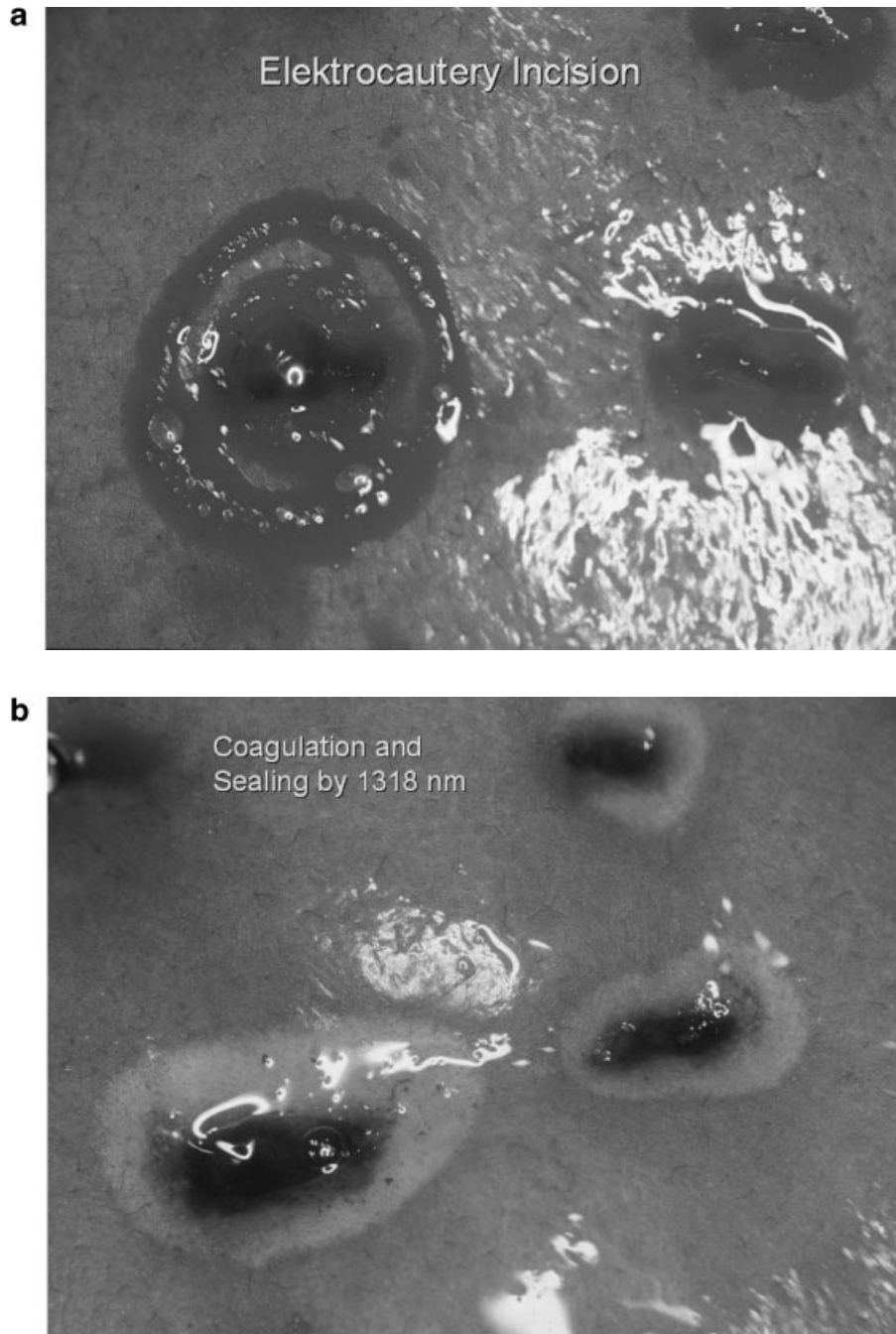


Fig. 1. **a:** One centimeter superficial electrocautery incision in a ventilated lung with bleeding and air leaks. **b:** The same lesions after 1,318 nm laser irradiation out of focus with effective coagulation, shrinking, and sealing of air leaks up to an artificial ventilation pressure of 20 cm H₂O.

tissue to get hemostasis and sealing of air leaks [5]. At the same time our group performed experimental and clinical studies comparing the 1,064 and 1,318 nm wavelengths of the Nd:YAG laser and published in 1988 [6] that the cutting and coagulation qualities of the 1,318 nm wavelength were much more feasible for lung parenchymal resections. Absorption of radiation in water is necessary to get cutting

of tissue with high water content like liver, spleen, or lung. To cause coagulation in an organ with great blood supply such as the lung scattering of radiation followed by penetration is needed. Graph 1 illustrates that the 10,600 nm CO₂ laser has a 10,000-fold higher absorption in water than the 1,064 nm Nd:YAG standard wavelength and thus is exclusively recommended to cut tissue [7]. Furthermore

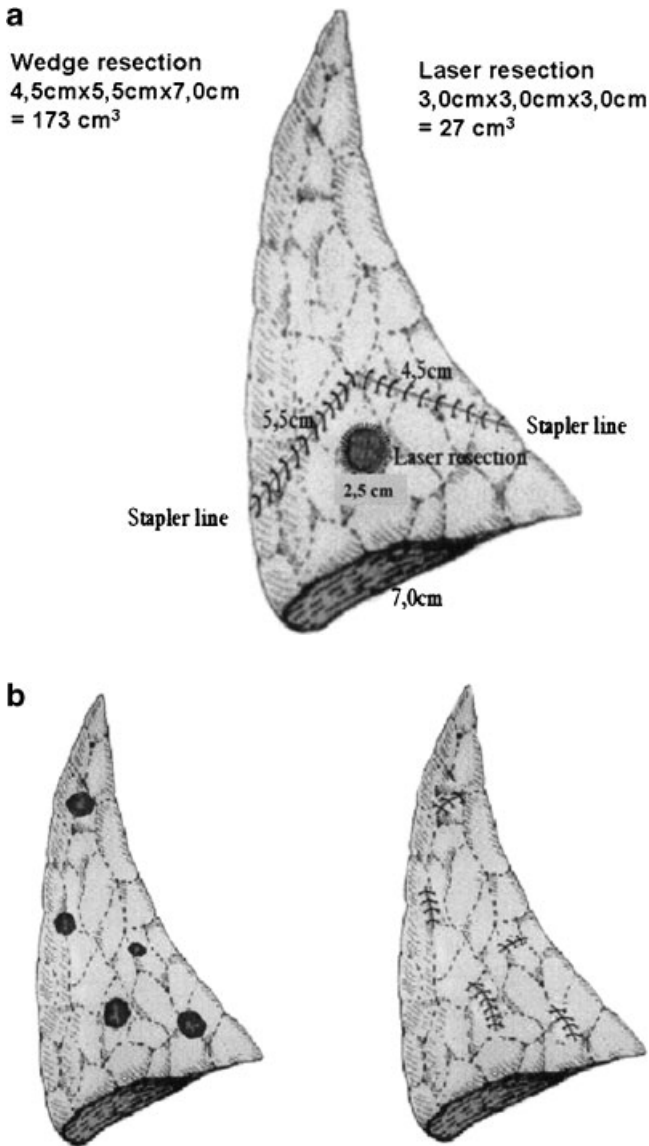
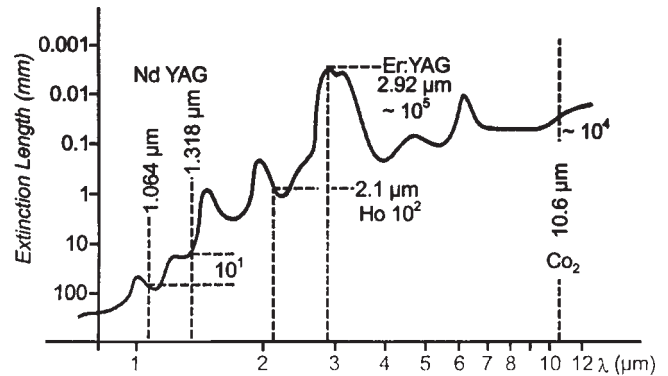


Fig. 2. **a:** Principle of precision laser resection is shown with a centrally located 2.5 cm metastasis of the lower lobe. With a rim of 5 mm (shrinkage included) tissue loss is 27 cm³ (laser) versus 173 cm³ (stapler). **b:** Principle of lobe sparing laser resection demonstrated with five metastases distributed throughout a lower lobe. Stapled wedge resections would remove virtually the complete tissue of the lobe which is preserved by precision laser resection.

our studies demonstrated that the 1,318 nm wavelength has a tenfold higher absorption in water compared to the 1,064 nm wavelength besides showing a nearly identical scattering and one-third the extinction in blood (not demonstrated) [6,8]. This is the explanation for the simultaneous and exclusive cutting, coagulation, and sealing qualities of 1,318 nm laser radiation for lung tissue. The difference is visible macroscopically by observing the layers and zones of tissue necrosis after laser irradiation (Fig 3a).



Graph. 1. Schematically simplified representation of the absorption spectrum of water (acc. to Bayly). The diagram exhibits the 1,064 and the 1,318 nm wavelengths of the Nd:YAG laser as well as the 10 times higher absorption capacity of the laser wavelength.

Three zones, a central crater of vaporized tissue (cutting area), a broad and light zone of coagulation, and a small corona of hyperemia at the periphery are identified after irradiation with 1,318 nm. Only two zones can be recognised following 1,064 nm irradiation. In this case the central crater of vaporization is surrounded by a broad zone with interstitial bleeding and there is only a minimal zone of coagulation (Fig 3b).

By modification of the resonator and special rotation of the crystal the Nd:YAG laser can emit the 1,318 nm wavelength. To achieve power densities of 20 kW/cm² sufficient to allow rapid resections deep into the center of a lobe it was necessary to almost double the mean energy efficiency of the Nd:YAG laser from 3% to 5%. Furthermore, the beam quality had to be improved to couple with thin 400 μm optical fibers without heating them or without loss of energy during transmission. Because of the 1,318 nm wavelength, specific high absorption in water, only selected fibers with very low water content could be used. For further transmission to the lung in the thoracic cavity a four lens focussing handpiece was developed allowing a nearly one-to-one projection of the focus. Last but not the least, a high-performance evacuation system is needed for rapid removal of the plume produced during photothermal laser resection [6,8,9].

In contrast to standard stapler wedge resection laser precision metastasectomy allows the surgeon to follow the outline of the tumor with a margin of 3 mm. Thus, the loss of tissue is only one-sevenths in comparison to the staple resection independent of the location of the metastasis. Thus significantly more metastases can be resected which allows saving of the involved lobe and its function (Fig. 2a,b). The tumor margin of 3 mm is oncologically safe because of the temperature between 600 and 700°C during resection. Within one-thousandth of a second a heat dissipation reaches the volume of 20–30 alveoli triggering their shrinking. The interstitial space, capillaries, small lymphatics, and blood vessels are closed simultaneously obstructing tumor cell spread. In this way metastases up to a diameter of 8 cm can




Fig. 3. **a:** View to the three different zones of lung tissue following 1,318 nm irradiation: Central mechanically solidly crater (4 mm), is surrounded by a 3 mm broad and light coagulation zone. At the periphery there is a small corona of hyperemia. **b:** View of lung tissue after 1,064 nm irradiation

with double power output compared to Figure 3a. Despite higher energy there are only two zones: A central mechanically unsolidly 3 mm crater is surrounded by a broad zone of diffuse interstitial bleeding.

be resected without bleeding. Only in the center of a lobe, at the level of segmental arteries and bronchi with diameters of 3 mm and more, is a suture of these structures necessary. For reconstruction of the lobe with several large laser resection areas and for creation of a new pleural surface we perform a running suture to reapproximate the cut edges of the pleura [9,10].

With this laser technique we have significantly expanded the eligibility of patients for enrollment in our study. We accepted any primary malignancy with single or multiple, synchronous or bilateral lung metastases. No limit to the number of metastases was given but assessment of functional and technical resectability by a thoracic surgeon experienced with this special laser technique was

mandatory. Furthermore, patients with suspected lymph node disease up to N2 status unilaterally and patients with previous chemotherapy were included.

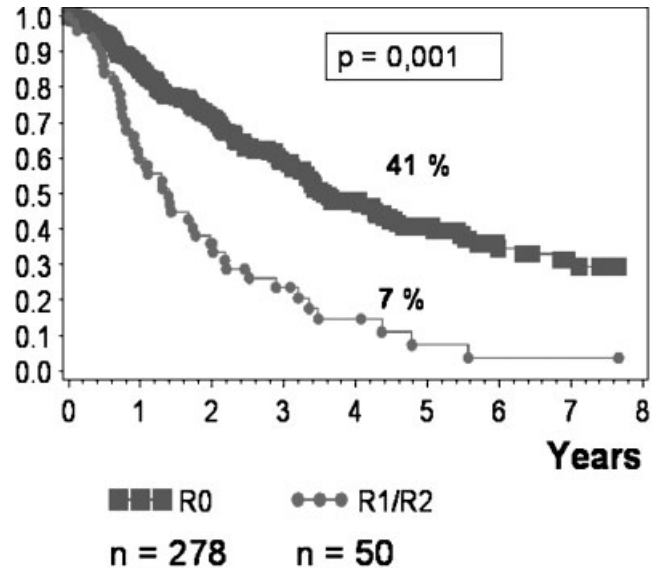
RESULTS

From 1/1996 to 12/2003 in 328 patients, 164 males and 164 females with a mean age of 61 years (range 20–80 years) a total of 3,267 nodules (10/patient) were removed. Despite the 40% central location of the nodules and a range of 3–80 mm of size precision laser resection was achieved in 93%. In only 7% of the patients lobectomy or a bronchoangioplastic procedure was necessary due to infiltration of major bronchovascular structures. Pathologic examination revealed 2,546 metastases (8/patient) and simultaneous 22% benign lesions like granulomas, intrapulmonary lymph nodes or chondrohamartomas. Lymph node metastases were found in 14% with complete resections and in 19% for all patients. Complete resection was achieved for 278 patients (85%) and in 15%, resection was classified as incomplete because of microscopic and macroscopic residual disease due to unexpected intraoperative miliary spread or to lymphangitic spread. One hundred and sixty five patients had unilateral thoracotomies with a mean of 3 metastases/patient complete resected and 113 patients had bilateral staged axillary thoracotomies with a mean of 13 metastases/patient complete removed. Ninety-one percent of the primaries were epithelial tumors with kidney cancer as the leading primary ($n = 112$) followed by colorectal ($n = 91$) and breast cancer ($n = 35$). Patients with sarcoma and malignant melanoma were only found in 6% and 3%, respectively.

Even with high numbers of metastases resected (mean 8/patient, maximal 124) precision 1,318 nm laser resection can be performed with low perioperative and postoperative morbidity. No 30-day mortality was observed in this series. Major postoperative complications included two cases with prolonged air leak (40 and 60 mets), two cases with intrapleural bleeding after decortication and redo surgery for metastases, and two cases with late pneumothorax (4 and 6 weeks after surgery) during sport. No further delayed air leaks or late pneumothoraces were observed with a mean of 31 months and maximal 7 years of follow-up time.

Graph 2 illustrates the 41% 5-year survival for all patients after complete resection of a mean of 8 metastases per patient. This result supports the value of complete resection as the most important prognostic factor and our strategy of repeated palpation of the deflated lung in order to resect any nodule which can be identified. The corresponding survival rate of 7% for incomplete resections is significantly poor despite the fact that all these patients had adjuvant chemotherapy or chemoradiotherapy.

Metastases to hilar or mediastinal lymph nodes were found in 19% by systematic lymphadenectomy in all patients. When complete resection of metastases and lymph nodes up to unilateral N2 status (R0N1/2) was achieved, we found a 5-year survival of 32% which was not significant ($P = 0.2$) to the 42% 5-year survival of patients

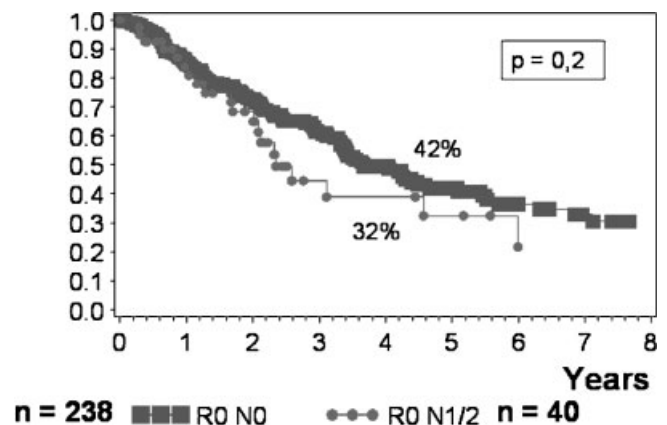


Graph. 2. Overall survival after complete (R0) resection versus significantly poorer incomplete (R1/R2) resection, $P = 0.001$ (squares = R0, bullets = R1/R2).

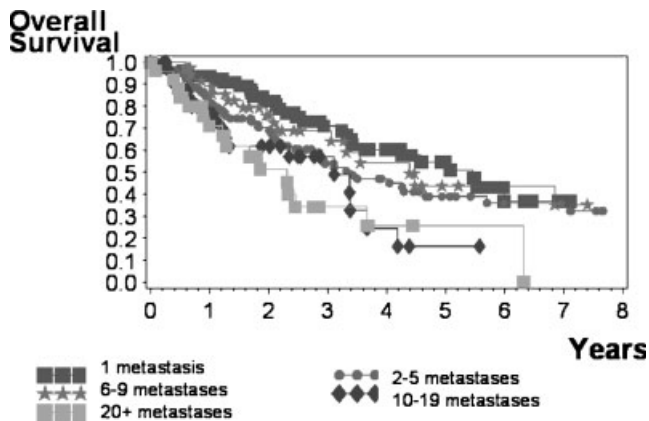
with complete resections without lymph node disease (R0N0) (Graph 3).

The comparison of unilateral to bilateral metastasectomy with a mean of 3 metastases/patient versus 13 metastases/patient revealed 5-year survival of 44% and 36%, respectively. Once more there was no statistical significance ($P = 0.35$) in the case of complete resection.

Graph 4 shows the survival of patients after complete resection of metastases in different groups from 1 up to 20 and more. The survival curves show no real cut-off point, seen when the nearly identical curve for 6–9 metastases is compared to the one for isolated metastasis. A solitary metastasis was only found in 28% in our series with the highest 5-year survival of 55%. In contrast to the majority of other groups, nearly half of the patients (49%) had four and



Graph. 3. Overall survival after complete resection of metastases with (R0 N1/2) or without (R0 N0) lymph node disease, no significance $P = 0.2$ (squares = R0 N0, bullets = R0 N1/2).



Graph. 4. Influence of the number of metastasis on survival (dark squares = 1 metastasis, bullets = 2–5 metastases, stars = 6–9 metastases, diamonds = 10–19 metastases, light squares = 20 and more metastases).

more metastases with a 5-year survival of 36%. Furthermore 21% of cases had 10 or more metastases with a 28% 5-year survival. Nine percent of our patients had 20 or more metastases and had a 5-year survival of 26%.

DISCUSSION

Nd:YAG lasers with the standard wavelength of 1,064 nm and flexible quartz fibers for transmission into cavities have been available since 1970 and had immediate and successful applications in gastroenterology for hemostasis and for vaporization of endoluminal tumors in urology and tracheobronchial procedures [11]. But it was not until 1985 when LoCicero first opened the debate on the use of lasers in open thoracic surgery with a CO₂ laser for hemostasis and sealing of air leaks which further turned out as pure-cutting laser [5]. Since 1986 we identified the 1,318 nm wavelength of the Nd:YAG laser by experimental and clinical studies to provide simultaneously the three qualities (cut, coagulate, seal) needed for deep parenchymal lung resection due to a tenfold higher absorption in water and only a one-third of extinction in blood. But the power output and the technical components of our laser prototype were not sufficient for routine work [6,8]. Other parallel groups in the United States, Japan, and Europe tried to introduce Nd:YAG laser with the standard wavelength of 1,064 nm, exclusively available with devices from serial production at that time, for parenchymal lung resection. But this wavelength could not provide sufficient cutting and coagulation qualities to handle extended resection to the center of a lobe [5,12–17]. A change was achieved when the above-described laser system delivering high-power densities to generate this 1,318 nm wavelength was developed in our institution.

Despite the fact that pulmonary metastasectomy today is routinely performed and accepted as curative potential treatment, there are only a few centers of thoracic surgery which offer metastasectomy for multiple or bilateral lesions [1–4]. The resection of multiple, large, hilar and centrally located metastasis is first of all a matter of surgical

technique. When electrocautery, clamps or stapler are used, the number and size of metastases that can be resected is limited and lobectomy rate using these techniques is reported to be 20–30% [2,4]. With the 1,318 nm laser we were able to achieve oncologic safe precision resection in 93% of 328 patients with 2,546 metastases in the range from 3 to 80 mm. Forty percent were centrally located. The lobectomy rate was only 7%. Lobectomy or broncho-angioplastic procedures were reserved for cases when metastases completely filled the lobe or infiltrated the central vessels.

Complete resection of all nodules palpable in the deflated lung in combination with systematic lymph node dissection is the most important prognostic factor and was achieved in 85% of this series despite a mean of 8 metastases/patient resected and lymph node disease in 19%. Metastasectomy can be performed more aggressively using the 1,318 nm laser as seen by the presence 22% benign lesions resected simultaneously with true metastases, a fact not yet reported by other groups but which must occur frequently given the nature of any operation based on palpating small lung nodules [9,18]. When complete resection was achieved, a 5-year survival of 41% similar to other groups was observed for all patients but no significant poorer outcome was seen for associated lymph node disease and bilateral resections.

Concerning the number of metastases which is often reported to be an independent prognostic factor with significance even between 1 and 2 metastases, we present in this series a high level of 8 metastases/patient resected with a maximum of 124 metastases in 1 patient. Forty-nine percent of our cases had four and more metastases with 36% 5-year survival, patients with 10 metastases (and more) and with 20 (and more) had 28% and 26% 5-year survival, respectively, with no real cut-off point in their survival curves. That means that the prognostic value of this factor is diminished if you can improve the technical ability to achieve complete resection.

Finally we conclude that this new 1,318 nm laser system improves any kind of lung parenchymal resection, facilitates complete resection of multiple bilateral and centrally located metastases and thus is lobe sparing.

REFERENCES

1. Mountain CF, McMurtrey MJ, Hermes KE. Surgery for pulmonary metastasis: A 20-year experience. *Ann Thorac Surg* 1984;38:323–330.
2. Venn GE, Sarin S, Goldstraw P. Survival following pulmonary metastasectomy. *Eur J Cardiothorac Surg* 1989;3:105–109.
3. Thomford NR, Woolner LB, Clagett OT. The surgical treatment of metastatic tumors in the lungs. *J Thorac Cardiovasc Surg* 1965;49:357–363.
4. Pastorino U, Buyse M, Friedel G, Ginsberg RJ, Girard P, Goldstraw P, Johnston M, McCormack P, Pass H, Putnam JB Jr. Long-term results of lung metastasectomy: Prognostic analyses based on 5206 cases. *The International Registry of Lung Metastases. J Thorac Cardiovasc Surg* 1997;113:37–49.
5. LoCicero J, Hartz RS, Frederiksen JW, Michaelis LL. New applications of the laser in pulmonary surgery. Hemostasis and sealing of air leaks. *Ann Thorac Surg* 1985;40:546–550.
6. Rolle A, Unsöld E, Ruprecht L, Permanetter W, Frank F. Morphologic aspects of Nd:YAG laser application (wave lengths 1064 nm and 1318 nm) on lung tissue. *Laser Med Surg* 1988;4:10–14.

7. Bayly IG, Kartha VB, Stevens WH. The absorption spectra of liquid phase H₂O, HDO, and D₂O from 0.7 micron to 10 micron. *Infrared Phys* 1963;3:211–223.
8. Rolle A, Thetter O, Häußinger K, Hallfeldt KKJ, Schmölder A. Einsatz des Neodym YAG Lasers in der Thoraxchirurgie. *Herz Gefäss Thorax Chir* 1989;3:85–91.
9. Rolle A, Pereszlenyi A. Laser resection of lung metastasis. *Multimedia Manual of Cardiothoracic Surgery* 2005; doi.10.1510/mmcts.2004.000570. http://mmcts.ctsnetjournal-s.org/cgi/collection/surgery_metastatic_lung
10. Rolle A. Laser applications in lung parenchyma surgery. *Med Laser Appl* 2003;18:271–280.
11. Häußinger K, Held E, Huber R. Endobronchial laser therapy, differential therapeutic use, and clinical value. *Klin Wochenschr* 1984;62:74–80.
12. LoCicero J, Hartz RS, Frederiksen JW, Michaelis LL. Laser assisted parenchyma-sparing pulmonary resection. *J Thorac Cardiovasc Surg* 1989;97:732–736.
13. Moghissi K. Experience in non-contact Nd:YAG laser in pulmonary surgery. *Eur J Cardiothorac Surg* 1988;2:87–94.
14. Kodama K, Doi O, Higashiyama M, Tatsuta M, Iwanaga T. Surgical management of lung metastases. Usefulness of resection with the neodymium:yttrium-aluminium-garnet laser with median sternotomy. *J Thorac Cardiovasc Surg* 1991;101:901–908.
15. Branscheid D, Krysa S, Wollkopf G, Bulzebruck H, Probst G, Horn M, Schirren J, Vogt-Moykopf I. Does ND-YAG laser extend the indications for resection of pulmonary metastases? *Eur J Cardiothorac Surg* 1992;6:590–597.
16. Kodama K, Doi O, Higashiyama M, Yokouchi H. Usefulness of Nd:YAG laser for the excision of multiple lung metastases and segmentectomy for primary lung cancer. *Kyobu Geka* 1992;45:51–55.
17. Mineo TC, Ambrogi V, Pompeo E, Nofroni I. The value of the Nd:YAG laser for the surgery of lung metastases in a randomized trial. *Chest* 1998;113:1402–1407.
18. Rolle A, Koch R, Alpard SK, Zwischenberger JB. Lobe-sparing resection of multiple pulmonary metastases with a new 1318 nm Nd:YAG Laser—First 100 patients. *Ann Thorac Surg* 2002;74:865–869.

